

# Maxillary Molar Distalization with Modified Trans Palatal Arch and Mini-Implants

Dr. Soja Sara George\*, Dr. Vijay Reddy\*\*, Dr. Deepti Reddy\*\*\*, Dr. Renu Parmar\*\*\*\*

## Abstract

*Mini implants have been used to eliminate headgear wear and to establish stationary anchorage. In this case report, distalization was achieved with a modified TPA with soldered J-hooks, which were coupled to palatal implant with e-chains. Two mini screws of dimension of 8 mm length and 1.8 mm diameter were placed interdental between 2<sup>nd</sup> premolar and 1<sup>st</sup> molar. The results showed that the maxillary molars were distalized bodily without causing anchorage loss or distal tipping, extrusion or rotation of the molars. Final results showed improvement in lip profile, smile esthetics and achievement of class I molar and canine relationships. In conclusion, palatal interdental implants can be used effectively for maintenance of anchorage and in space-gaining procedures.*

**Key words:** Mini screws, Distalization, Maxillary molars.

Angle's Class II Division I malocclusion has been described as the most common malocclusion in orthodontic practice. In treatment of Angle's class II malocclusion with anterior crowding and increased over jet, distalization of maxillary molars or extraction of premolars is often the preferred treatment alternative.<sup>1</sup>

Patients with orthognathic facial profiles, end-on inter-arch molar relationship, mild to moderate space requirement (nearly 3-4 mm on either side) and a good soft tissue balance are often ideal candidates for maxillary molar distalization. However, distalization of the permanent molars has been one of the most difficult biomechanical problems in conventional orthodontics, particularly in adult patients.

Various treatment modalities for molar distalization have been tried including those that depend on patient compliance, such as extra-oral traction using headgears, removable appliances with finger

springs, Wilson arches, and sliding jigs with Class II inter-maxillary elastics. On the contrary, techniques that rely less on patient cooperation have also been routinely used like repelling magnets, transpalatal arches, compressed coil springs, and the Herbst appliance. Though all these techniques distalize maxillary molars effectively however, the major limiting factor is anchor loss; characterized by distal tipping of maxillary molars, proclination of teeth anterior to the molars resulting in an increased overjet.<sup>2</sup>

With the introduction of skeletal anchorage system it has now become possible to translate permanent molars distally whilst simultaneously correcting maxillary incisor protrusion, crowding, and dental asymmetries without anchor loss. Temporary anchorage devices such as endosseous implants, miniplates, onplants, or mini screws provide absolute anchorage for many complicated orthodontic tooth movements including intrusion, en-masse retraction and distalisation of molars.

The case report demonstrates an effective technique of maxillary molar distalization in tandem with anchorage preservation using miniscrew supported transpalatal arch.

\* Consultant orthodontist, Hyderabad, Andhra Pradesh.

\*\* Professor, Department of Orthodontics, Sri Sai College of dental surgery, Vikarabad, Andhra Pradesh.

\*\*\* Professor & Head of the department, Department of Orthodontics, Sri Sai College of dental surgery, Vikarabad, Andhra Pradesh.

\*\*\*\* Consultant orthodontist, Bangalore, Karnataka.

**Correspondence address:** sara18259@gmail.com

**CASE REPORT:**

A 13 Yr old female presented with the chief complaint of irregularly placed upper front teeth and an unpleasing smile.

On extra-oral examination, the patient exhibited convex profile with slightly incompetent lips (Interlabial gap of 5mm), acute naso-labial angle, a consonant smile arc, adequate incisal display at rest (4 mm) and full maxillary incisal display during smile, with a mild degree of chin retrusion and prominent nose. (Figure 1)

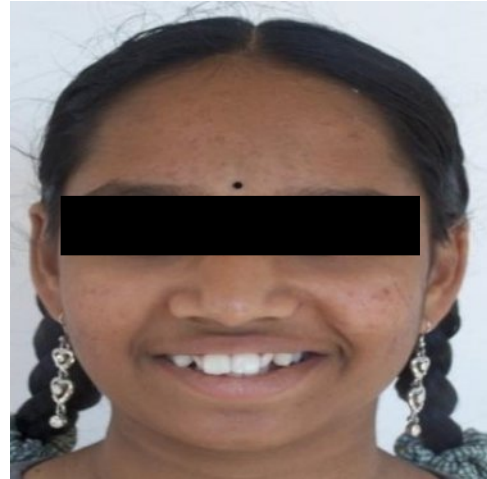
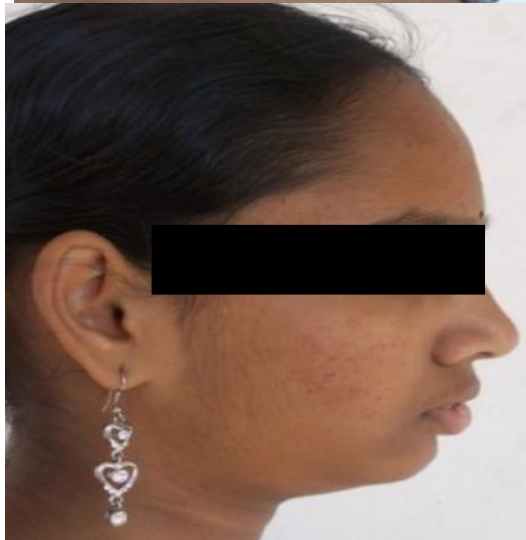
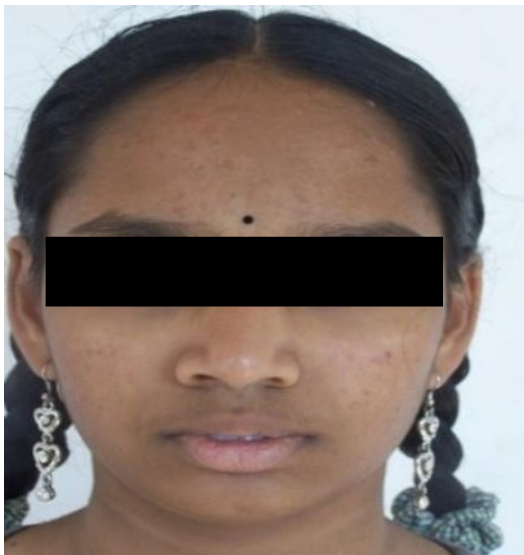Fig. 1 – Pretreatment extra oral photographs: 13 year old patient with a slightly convex profile, mild retro-positioned chin, consonant smile arch with minimal lip incompetence



Intra-orally, the patient demonstrated an end-on inter-arch molar and canine relationship on both, the left and the right sides. Peg shaped maxillary lateral incisors (12, 22), a moderate degree of maxillary (04 mm) and mandibular (06 mm) anterior crowding, an increased overjet (04 mm) and non-coinciding dental midlines. (Figure 2)

Lateral cephalogram showed, class I skeletal pattern ( $ANB=02^\circ$ ) with vertical growth pattern of  $34^\circ$  (GoGn - SN) and the CVMI – showed 20-30% growth remaining. Steiner analysis showed that both the upper and lower incisors were proclined and protracted. The nasolabial angle was acute at  $85^\circ$ . There were no signs and symptoms of temporomandibular disorders. Distance from the pterygoid vertical to distal of maxillary molar showed that maxillary molar was mesialised by 3mm. Based on the cephalometric findings, the patient was diagnosed with skeletal Class I with severe crowding.

Treatment objectives were to align and level the teeth in both arches, to achieve Class I canine and molar relationship and ideal over jet and overbite, reshaping of peg shaped laterals, to obtain a balanced facial profile and to improve smile

esthetics. The treatment objectives could be achieved by using one of the options: 1) Extraction of all first premolars. Extraction treatment was not opted considering her age, profile and prominent nose. Even though her profile was slightly convex with mild degree of chin retrusion, it was acceptable according to Indian soft tissue norms.<sup>3</sup> In spite of her upper incisor proclination, her facial esthetics was balanced and any mild degree of

chin retrusion would be corrected with remaining growth (CVMI showed 20-30 % growth remaining). 2) Distalization of the maxillary molars with mini-implants was opted, as this would correct the class II molar and canine relation, resolved crowding and proclination of the anteriors.

Conventional method of maxillary molar distalization (Eg: pendulum appliance, headgears) were not used due their adverse effects of

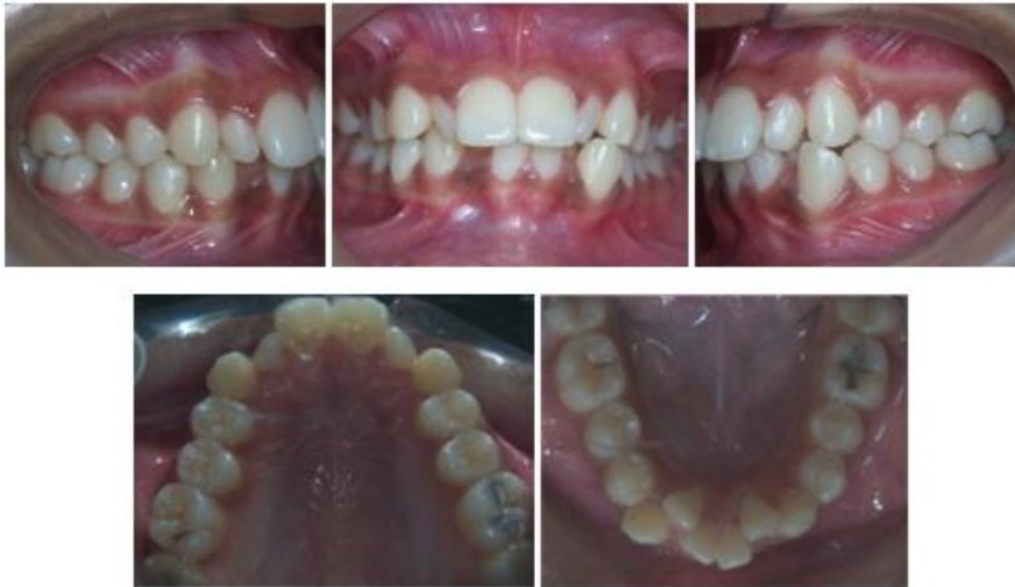

Fig. 2- Pretreatment intra-oral photographs demonstrating peg-shaped maxillary laterals with end-on molar and canine relationship bilaterally and lower anterior crowding

anchorage loss, increasing the mandibular plane angle, proclination of anteriors and due to the demand of patient compliance. Distalization with mini implant was planned, as it gave bodily movement of maxillary molars and vertical control.

The treatment proposed was, distalization of the maxillary molars to correct the end-on molar relationship, to resolve crowding and maxillary teeth protrusion using palatally placed mini screws for anchorage.

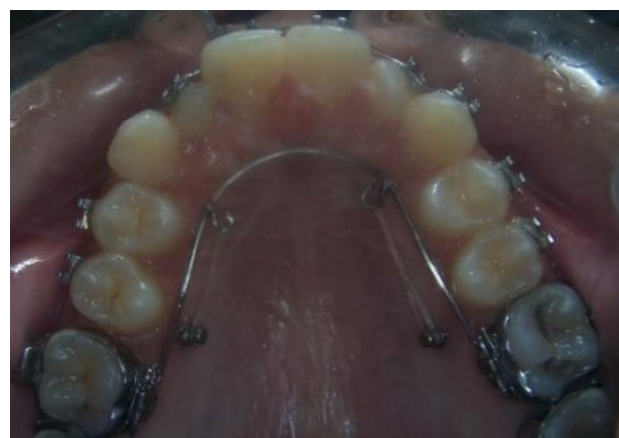

Fig. 3: Miniscrews placed palatally between the 2<sup>nd</sup> premolar and the maxillary 1<sup>st</sup> molar with customized TPA with soldered J-hooks

Two mini screws (Orlus, Ortholution, Seoul, Korea) of dimension of 8 mm length and 1.8 mm diameter were placed interdentally between 2<sup>nd</sup> premolar and 1<sup>st</sup> molar. A Modified transpalatal arch (TPA)

of 0.036-inch (0.9 mm) hard round stainless steel with soldered J-hooks was constructed in a way to extent it bilaterally from one molar to the other. (Figure 3)

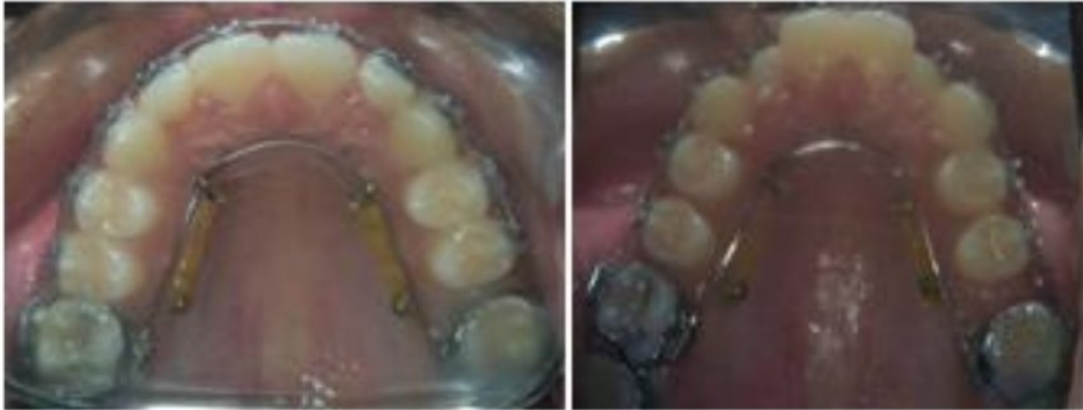

Fig. 3 Miniscrews placed palatally between the 2<sup>nd</sup> premolar and the maxillary 1<sup>st</sup> molar with customized TPA with soldered J-hook

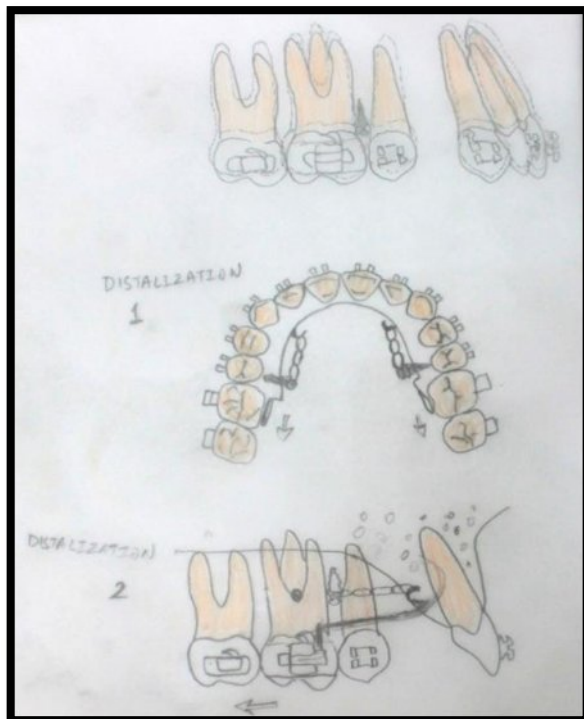


Fig 4. Schematic representation with the biomechanical illustration

The J-hooks were positioned in the canine region and the distalizing force (200 gm) was generated

by e-chain applied from the J-hooks to the mini-screws. The screws were placed 6-7 mm below the free gingival margin, which was nearly the region of maxillary molar trifurcation. (Figure 4) Thus, the elastic traction was applied in a way that, the distalizing force would pass close to the centre of resistance of maxillary molars. Consequently, the molars were translated bodily without any untoward rotation or tipping. Also, while no anchorage was derived from the anterior teeth accordingly, there was no proclination of the maxillary anteriors. (Figure 5)

The patient was reviewed every 4 weeks and the e-chain changed to maintain a constant distalization force. The first molars were distalized into an over-corrected Class I molar relationship, which was confirmed in both post treatment radiographs. (Figure 6 and 7)

The mini screws were retained in-situ post distalization, and the TPA- miniscrew assembly alternatively used as a retainer during the second phase of fixed orthodontic mechanotherapy.

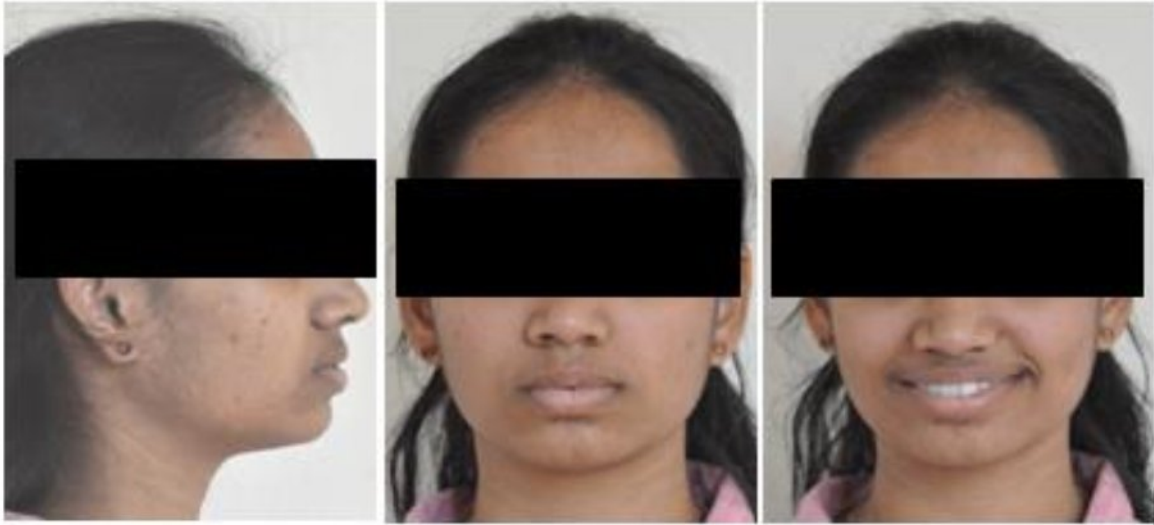

Fig 6–Post treatment extra oral photographs

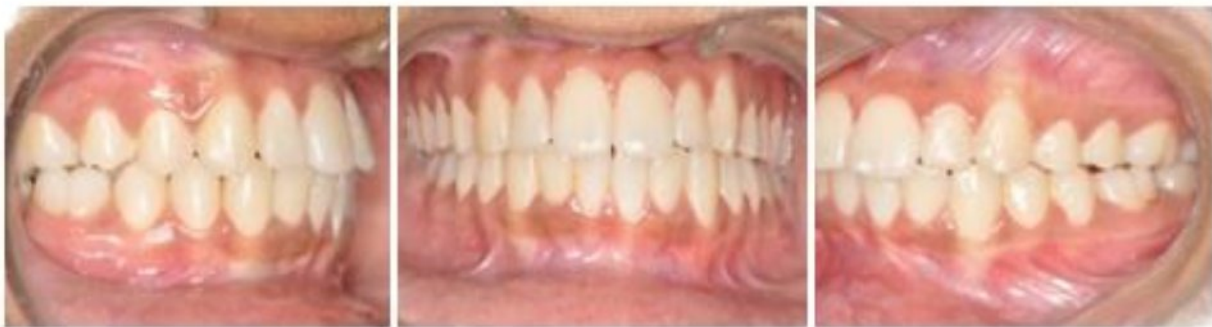

Fig. 7– Post treatment intraoral photographs-The maxillary peg shaped laterals were built-up and normal over-jet and over-bite established. The smile esthetics is many folds enhanced and the facial balance is maintained.

This included a strap-up with 0.022" slot MBT prescription of the segment anterior to the distalized molars. The arches were aligned, leveled and the space gained was utilized to decrowd the maxillary arch and for build-up of the peg laterals to normal morphology.

Post treatment facial photographs showed improvement in lip profile and smile esthetics. (Figure 6) Class I molar and canine relationships were observed with a 3mm over jet and a 2mm overbite. Cephalometric superimposition showed that the maxillary molars were distalised bodily by 3mm. Mandibular plane angle reduced to  $31^{\circ}$  and

nasolabial angle to  $95^{\circ}$ , which were in normal range.

#### DISCUSSION

Molar distalization with head gears had disadvantages of patient compliance and duration of wear. Various other intra oral distalizing appliances used, cause anchor loss with maxillary incisor proclination and increased over-jet.

In this case report, molar distalization was achieved with a modified TPA with soldered J-hooks, which were coupled to palatal implant with e-chains. This mini screw distalization system effectively distalized molars into class I

relationship, without causing anchorage loss or distal tipping, extrusion or rotation of the molars. For the implant placement on the buccal side, where the inter-radicular space is smaller, the screw would have to be inserted more apically. But such placement has been associated with inflammation leading to mini screw failure and can cause patient discomfort. As the palatal mucosa is highly keratinized, the mini implant can be placed as high as necessary without complications.<sup>4</sup>

## CONCLUSION

The advantages of mini screw anchorage over conventional mechanics include the elimination of patient compliance and the provision of absolute anchorage, with no proclination of anteriors or

untoward tipping or rotation of the teeth distalized. Further the amount of movement is controllable and it is also possible to apply asymmetric force on each side.<sup>4,3</sup>

With the introduction of miniscrews in the orthodontic armamentarium, molar distalization which was once considered difficult to achieve, can now be performed with good prediction and efficiency.<sup>5, 6</sup> Use of palatal implants has the advantages of availability of more inter-dental space than buccal inter-dental space. However, disadvantage of palatal inter-dental implants are the possibilities of movement of adjacent teeth, also difficulty in surgical procedure than for the buccal implants.

## References

1. Fibro-osseous lesions of the jaws. J Oral Maxillofac Surg 1993; 51:828–35.
2. Speight PM, Carlo R. Maxillofacial fibro-osseous lesions Mini-symposium. Current Diagnostic Pathology 2006; 12: 1–10.
3. Waldron CA. Fibro-osseous lesions of the jaws. J Oral Maxillofac Surg. 1985; 43(4):249-62.
4. Makek MS. So called "fibro-osseous lesions" of tumorous origin. Biology confronts terminology. J Craniomaxillofac Surg. 1987;15(3):154-67.
5. Eversole R, Su L, ElMofty S. Benign fibro-osseous lesions of the craniofacial complex. A review. Head Neck Pathol. 2008;2(3):177-202
6. Wong GL. Paracrine interactions in bone secreted products of osteoblasts permit osteoclasts to respond to parathyroid hormone. J Chem 1984; 259:4019–22.
7. Penfold CN, McCullagh P, Eveson JW, Ramsay A. Giant cell lesions complicating fibro-osseous conditions of the jaws. Int J Oral Maxillofac Surg 1993; 22:158–62.
8. Waldron CA, Shafer WG. The central giant cell reparative granuloma of the jaws. Am J ClinPathol 1966; 45:437–47
9. MacDonald-Jankowski DS. Fibro-osseous lesions of the face and jaws. ClinRadiol 2004;59:11–25

**Conflict of Interest: None Declared**